

Treatment of osteoarthritis with autologous and microfragmented adipose tissue

Kristoffer Weisskirchner Barfod¹ & Lars Blønd²

ABSTRACT

INTRODUCTION: Osteoarthritis (OA) is the leading cause of disability in elderly people. Several non-invasive solutions have been proposed with varying success rates. Recently, new therapeutic approaches, such as the use of minimally manipulated tissue products, have gained increasing popularity. The purpose of this study was to investigate the safety and feasibility of a single intra-articular injection of autologous, microfragmented adipose tissue in patients with knee OA.

METHODS: The study was performed as a prospective cohort study. Microfragmented adipose tissue was obtained using a minimal manipulation technique (Lipogems). The safety of the procedure was evaluated by recording the type and incidence of any adverse events at three months. The clinical outcomes were determined using the Knee injury and Osteoarthritis Outcome Score (KOOS) scale at three, six and 12 months of follow-up.

RESULTS: Twenty patients were included in the study and all participated in the follow-up. Only one adverse event was registered; a patient complaint of cosmetic changes to the abdominal subcutaneous tissue. The improvements in KOOS were significant at all follow-up. At one year, KOOS pain had improved by 14 points, symptoms by seven, activity of daily living by 13, sports by 19 and quality of life by 15.

CONCLUSIONS: The intra-articular injection of autologous, microfragmented adipose tissue for treatment of knee OA seems safe. Randomised controlled trials are needed to elucidate the efficacy of the treatment.

TRIAL REGISTRATION: This study was registered in ClinicalTrials.gov (NCT02697682).

FUNDING: none.

Osteoarthritis (OA) of the knee is a destructive joint disease causing degeneration of cartilage, damage to the underlying bone and morphological changes to the joint [1]. It is a major public health concern due to the increased life expectancy of the ageing population [2]. No approved medical treatment that reverses the morphological changes currently exists. Conventional treatment includes physiotherapy, pain killers, braces and, in the end-stage, surgical knee replacement [3].

During the past decade, researchers have explored the regenerative potential of mesenchymal stem cells derived from adipose tissue in the treatment of OA [4,

5]. The complex regulatory issues applying for enzymatically treated and/or expanded cells have led to the development of minimally manipulated tissue [6]. Lipogems is one such system where the adipose tissue is mechanically microfragmented and washed until free of pro-inflammatory oil and blood residues. The resulting product is composed of small intact adipose tissue clusters (250-650 microns) containing pericytes retained within an intact stromal vascular niche. Pericytes are cells situated at the external wall of the capillaries, which detach after injury or inflammation from the capillaries and convert into activated regenerative mesenchymal stem cells [7]. The activated pericytes are said to release exosomes filled with regenerative factors that allow for tissue repair and regeneration [7]. The product is safe (obtained the US Food and Drug Agency's approval in 2014), and in case series it has been demonstrated to be effective in the treatment of various pathologies including knee, ankle, hip and shoulder OA [8], but level-one evidence is lacking. The Lipogems system is being introduced worldwide these years, why it is of utmost importance to investigate the safety, feasibility and efficiency of the product. A small safety study investigating injection with Lipogems in 26 knees was published in November 2018 showing no severe adverse events, but the study did not investigate donor site morbidity [9].

The purpose of the present study was to investigate short-term safety issues and the feasibility of using autologous, microfragmented adipose tissue processed with the Lipogems system for treatment of knee OA.

METHODS

The study was an independent, non-profit prospective cohort study following the Strengthening the Reporting of Observational Studies in Epidemiology guidelines for reporting of observational studies.

The study was performed at the outpatient clinic of the Orthopaedic Department at Zealand University Hospital, Koege, Denmark, in the period from April 2016 to July 2017 with inclusion and treatment of patients spanning the first three months of the study period.

Study design and population

Patients referred to the department who were suffering

ORIGINAL ARTICLE

1) Sports Orthopedic Research Center – Copenhagen (SORC-C), Department of Orthopedic Surgery, Hvidovre Hospital
2) Department of Orthopedic Surgery, Zealand University Hospital Køge, Denmark

Dan Med J
2019;66(10):A5565

from long-lasting knee pain (more than six months) and OA of the knee (Kellgren-Lawrence grade 1-4) were eligible for inclusion if aged 18-70 years, expected to be able to attend rehabilitation and post-examinations, able to speak and understand Danish and able to provide their informed consent. Patients were excluded from the study if they had varus or valgus malalignment of the knee exceeding five degrees, rupture of the cruciate ligaments of the knee, a BMI above 35 kg/m² or an American Society of Anesthesiologists score higher than or equal to three. Patients were informed of the study verbally and in writing and, on an informed basis without any pressure, allowed 24 hours of reflection before written consent was obtained.

Patients were treated with a 10-ml intra-articular injection with autologous, microfragmented adipose tissue prepared using the Lipogems system.

Harvesting of the adipose tissue

Harvesting of adipose tissue was performed under sterile conditions in the operating theatre. The patient was positioned in the supine position, and an area just below the umbilicus of approximately 8 cm (cranio-caudally) × 20 cm (laterally) was marked on the skin with a surgical marker. Under sterile conditions, the adipose tissue was prepared for harvesting by injection of a suspension of 20 ml carbocain 1%, 200 ml isotonic saline, 0.2 ml adrenaline and 10 mmol bicarbonate using a disposable 17-G blunt cannula connected to a luer-lock 60-ml syringe. The fat was then harvested using a 13-G blunt cannula connected to a Vaclock 20-ml syringe. At the end of the procedure, the skin was closed with a plaster.

Processing of the adipose tissue with the Lipogems device

The harvested fat was immediately processed in the Lipogems processing kit (Lipogems International Spa, Italy), a disposable device that progressively reduces the size of the adipose tissue clusters while eliminating oily substances and blood residues with pro-inflammatory properties [8, 10]. The entire process, carried out in one surgical step, was performed in immersion in a physiological saline solution minimising any traumatic action on cell products. The resulting microfragmented tissue was collected in a 60-ml syringe and positioned for decanting the excessive saline solution. Finally, the product was transferred into ten 1-ml syringes.

Microfragmented adipose tissue injection

Microfragmented adipose tissue was injected under sterile conditions with the patient in the supine position on an examination bench with the affected knee stretched. The superior pole of the patella was palpated, and the femoral condyle was marked with a sur-

gical marker. The suprapatellar recess was located by ultrasound, and a 21-G syringe was introduced in the suprapatellar recess.

Follow-up visits and outcome measures

Patients were followed-up at three, six and 12 months by a designated project nurse. All data were collected by the nurse through patient-reported questionnaires.

The primary outcome was safety at three months, assessed by recording any adverse event at three months. An adverse event was defined as any event caused by the treatment leading to a less preferable situation for the patient. Patients were screened for donor site morbidity (infection, swelling, pain) and injection site morbidity (infection, swelling, pain). Secondary outcomes were adverse events after six and 12 months and improvements in the clinical outcomes measured by the Knee injury and Osteoarthritis Outcome Score (KOOS) [11]. The KOOS holds 42 items in five separately scored subscales: Pain, Symptoms, Function in daily living, Function in Sport and Recreation, and knee-related Quality of Life. The five patient-relevant subscales of KOOS were scored separately and transformed into a 0-100 scale, with zero representing extreme knee problems and 100 representing no knee problems. A change of ten points or more was considered clinically relevant [11].

Sample size and power

Being a pilot study, 20 patients were included based on logistical considerations and the sample sizes of previous pilot studies. No power calculation was made.

Statistical analysis

Descriptive data were presented as means and standard deviations for continuous data and as number of pa-

TABLE 1

Baseline data. Patient demographics and Knee injury and Osteoarthritis Outcome Scores.

	Mean ± SD
Age, yrs	49 ± 9
Weight, kg	89 ± 22
Height, cm	170 ± 23
<i>KOOS</i>	
Pain	57 ± 18
Symptoms	64 ± 18
ADL	63 ± 17
Sports	24 ± 23
QoL	31 ± 16

ADL = activities of daily living; KOOS = Knee injury and Osteoarthritis Outcome Score; QoL = quality of life; SD = standard deviation.

tients for categorical data. Density plots of data were performed and visually evaluated for normality. Comparison of baseline KOOS scores at three, six and 12 months was performed using repeated measurement ANOVA. The level of significance was set at $p < 0.05$.

Trial registration: This study was registered in Clinical-Trials.gov (NCT02697682).

RESULTS

Twenty patients were included in the study from April to July 2016, all of whom participated in the one-year follow-up. Baseline data are presented in **Table 1**.

One patient complained of cosmetic irregularity at the donor site due to harvesting of too much tissue at one location. Secondly, this was corrected by a plastic surgeon where after the patient obtained a cosmetically satisfactory result. Patients reported moderate to severe pain at the donor site in the weeks following the procedure, but no persistent pain at the donor site was reported at the three-month follow-up (Table 1).

A statistically significant improvement in KOOS was seen in all subscales. At the 12-month follow-up, pain improved 14 points, symptoms seven points, activities of daily living (ADL) 13 points, sports 19 points and quality of life (QoL) 15 points. Ten points or more is considered a clinically relevant improvement [11], and as such, only four of the five subscales (pain, ADL, sports and QoL) showed a clinically important improvement (**Figure 1** and **Figure 2**). At this time, 15 out of 20 patients would go for the procedure again, two would not and three did not know. Two of the patients who did not respond to the treatment have later responded positively to surgical treatment by lengthening of the lateral retinaculum. Both were diagnosed as having patellofemoral pain based on hyper pressure due to a tight lateral retinaculum.

DISCUSSION

No safety issues were raised in relation to the Lipogems system. One patient complained of cosmetic changes to the abdominal subcutaneous tissue, but this must be considered a minor complication and was probably due to lack of experience with lipoaspiration on the part of the orthopaedic surgeon harvesting the fat. The surgeon was trained and supervised for the first five cases by an experienced consultant plastic surgeon, but still a learning curve effect must be expected. Pain during the procedure was light (visual analogue scale (VAS) 1.8) but increased in the week after the treatment where pain levels rose to VAS 4.4 before declining to VAS 1 after one month and VAS 0.2 after three months. These findings are in line with those reported by Panchal et al [9] and support future investigation of the efficacy of the procedure.

FIGURE 1

Mean (95% confidence interval) improvement in Knee injury and Osteoarthritis Outcome Score (KOOS) subscales from baseline to three, six and 12 months of follow-up. A change of ten points is considered clinically relevant.

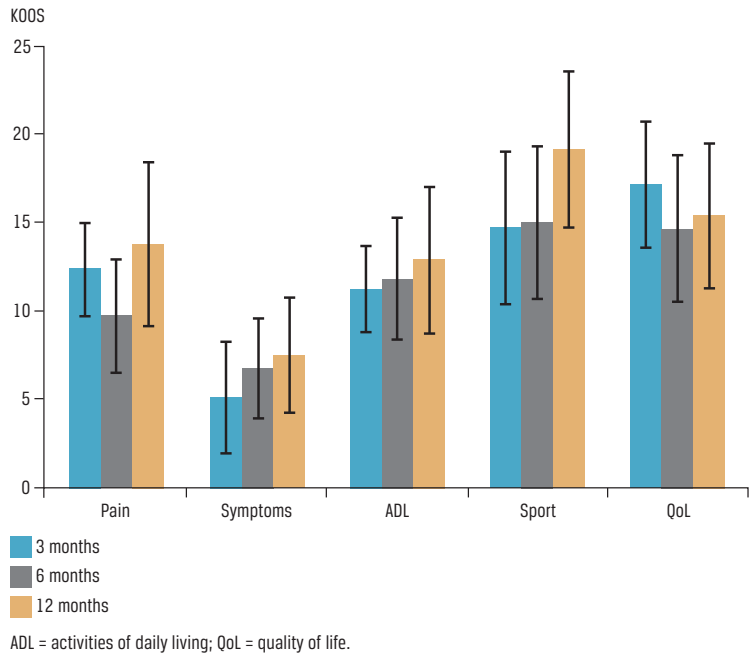
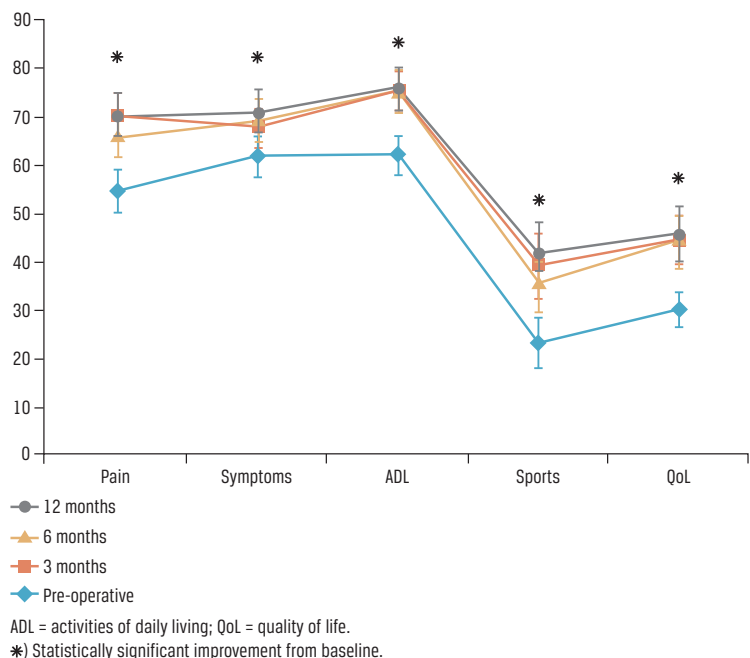


FIGURE 2

The five subscales of the Knee injury and Osteoarthritis Outcome Score at baseline and at 3, 6 and 12 months. The data are shown as mean (95% confidence interval).



Liposuction is one of the most commonly performed aesthetic procedures and few complications are reported, but the literature is very sparse concerning donor site morbidity in patients with minimal lipoaspiration like the one being performed in the present study. In 2017, Comella and colleagues reported on safety issues after abdominal liposuction and autologous stem cell therapy [12]. They reported 3.4% adverse events including soreness at the site of harvest. No other complications were reported, but no systematic investigation of donor site morbidity was described in the paper. Possibly, complications are underestimated and underreported by caregivers. In larger body-contouring procedures, minor wound complications have been reported in 6% of cases and fatal complications in 19-20 per 100,000 [13, 14]. It seems reasonable to conclude that minimal lipoaspiration like the one performed in the present study is safe but not pain free. Patients should be informed that pain and discomfort will be present at the time of the procedure and one month afterwards, with discomfort peaking one week after the procedure.

No adverse events were found in the treated knees or at the injection sites. This correlates well with the literature where no superficial infections or septic arthritis have been reported after injection with microfragmented adipose tissue [14]. Comparing with other types of knee injection, the risk of septic arthritis is probably very limited, but present. Infection rates after injection with corticosteroids or hyaluronate are not reported in the literature, but case reports exist and, in a Korean study, an increase in septic arthritis rates was attributed to increased use of intra-articular agents [15].

No serious adverse effects like infection or tumour formation have been observed in the treatment of OA with mesenchymal stem cells or minimally manipulated tissue products [16]. More than 17,000 scientific articles have been published reporting on the treatment of more than 320,000 patients [17]. No severe safety issues have been raised [18]. As such, it seems reasonable to conclude that local intra-articular injection of autologous, microfragmented adipose tissue in the knee is a feasible and safe procedure.

The patients experienced a statistically significant and clinically relevant improvement in KOOS on four of the five subscales; however, the effect might be explained by natural variation in the disease or a placebo effect as the study included no control group and no blinding was possible.

One randomised clinical trial (RCT) has been published that studied treatment of OA in the knee with minimally manipulated tissue [19]. It was a prospective, single-blind, placebo-controlled trial including 25 patients with bilateral OA of the knee. The patients

were randomised to receive bone marrow aspirated from the iliac crest into one knee and saline placebo into the other. There was a dramatic and statistically significant pain relief in both knees after one and six months, but no difference between the knees indicating that placebo treatment with saline worked just as well as the bone marrow aspirate. Assessing the pain literature more broadly, sham surgical procedures for pain intervention have been shown to yield significant pain improvements. The effect was largest within the first month of sham surgery but remained present at six months [20].

The main limitation of the study was the small sample size rendering it impossible to investigate for safety of rare complications. Another limitation was the method used for implantation of the microfragmented adipose tissue in the supra patellar pouch of the knee. As ultrasonography was not routinely performed, a risk of misplacement of the graft outside the knee joint was present.

Despite these limitations, we can conclude that the treatment of knee OA with intra-articular injection with autologous, microfragmented and minimally manipulated adipose tissue seems safe. High-quality RCTs are needed to elucidate the efficacy of the treatment.

CORRESPONDENCE: Kristoffer Weisskirchner Barfod.

E-mail: kbarfod@dadlnet.dk

ACCEPTED: 25 June 2019

CONFLICTS OF INTEREST: none. Disclosure forms provided by the authors are available with the full text of this article at Ugeskriftet.dk/dmj

LITERATURE

- Goldring MB, Goldring SR. Articular cartilage and subchondral bone in the pathogenesis of osteoarthritis. *Ann N Y Acad Sci* 2010;1192:230-7.
- Gupta S, Hawker GA, Laporte A et al. The economic burden of disabling hip and knee osteoarthritis (OA) from the perspective of individuals living with this condition. *Rheumatology* 2005;44:1531-7.
- Hawker GA, Mian S, Bednis K et al. Osteoarthritis year 2010 in review: Non-pharmacologic therapy. *Osteoarthr Cartil* 2011;19:366-74.
- Pak J, Lee JH, Kartolo WA et al. Cartilage regeneration in human with adipose tissue-derived stem cells: current status in clinical implications. *Biomed Res Int* 2016;2016 :4702674. Epub 2016 Jan 6.
- Ruetze M, Richter W. Adipose-derived stromal cells for osteoarticular repair: trophic function versus stem cell activity. *Expert Rev Mol Med* 2014;16:e9.
- Åhrlund-Richter L, De Luca M, Marshak DR et al. Isolation and production of cells suitable for human therapy: challenges ahead. *Cell Stem Cell* 2009;4:20-6.
- Caplan AL, Correa D. The MSC: an injury drugstore. *Cell Stem Cell* 2011;9:11-5.
- Tremolada C, Colombo V, Ventura C. Adipose tissue and mesenchymal stem cells: state of the art and lipogems® technology development. *Curr Stem Cell Reports* 2016;2:304-12.
- Panchal J, Malanga G, Sheinkop M. Safety and efficacy of percutaneous injection of lipogems micro-fractured adipose tissue for osteoarthritic knees. *Am J Orthop (Belle Mead NJ)* 2018;47.
- Bianchi F, Maioli M, Leonardi E et al. A new nonenzymatic method and device to obtain a fat tissue derivative highly enriched in pericyte-like elements by mild mechanical forces from human lipoaspirates. *Cell Transplant* 2013;22:2063-77.
- Roos EM, Lohmander LS. The Knee injury and Osteoarthritis Outcome Score (KOOS): from joint injury to osteoarthritis. *Health Qual Life Outcomes* 2003;1:64.
- Comella K, Parlo M, Daly R et al. Safety analysis of autologous stem cell therapy in a variety of degenerative diseases and injuries using the stromal vascular fraction. *J Clin Med Res* 2017;9:935-42.
- Ezzeddine H, Husari A, Nassar H et al. Life threatening complications post-liposuction. *Aesthetic Plast Surg* 2018;42:384-7.

14. Fischer JP, Wes AM, Serletti JM et al. Complications in body contouring procedures: An analysis of 1797 patients from the 2005 to 2010 american college of surgeons national surgical quality improvement program databases. *Plast Reconstr Surg* 2013;132:1411-20.
15. Schumacher HR, Chen LX. Injectable corticosteroids in treatment of arthritis of the knee. *Am J Med* 2005;118:1208-14.
16. Wakitani S, Okabe T, Horibe S et al. Safety of autologous bone marrow-derived mesenchymal stem cell transplantation for cartilage repair in 41 patients with 45 joints followed for up to 11 years and 5 months. *J Tissue Eng Regen Med* 2011;5:146-50.
17. Mason C, Manzotti E. Regenerative medicine cell therapies: numbers of units manufactured and patients treated between 1988 and 2010. *Regen Med* 2010;5:307-13.
18. Culme-Seymour EJ, Davie NL, Brindley DA et al. A decade of cell therapy clinical trials (2000-2010). *Regen Med* 2012;7:455-62.
19. Shapiro SA, Kazmerchak SE, Heckman MG et al. A Prospective, single-blind, placebo-controlled trial of bone marrow aspirate concentrate for knee osteoarthritis. *Am J Sports Med* 2017;45:82-90.
20. Gu AP, Gu CN, Ahmed AT et al. Sham surgical procedures for pain intervention result in significant improvements in pain: systematic review and meta-analysis. *J Clin Epidemiol* 2017;83:18-23.